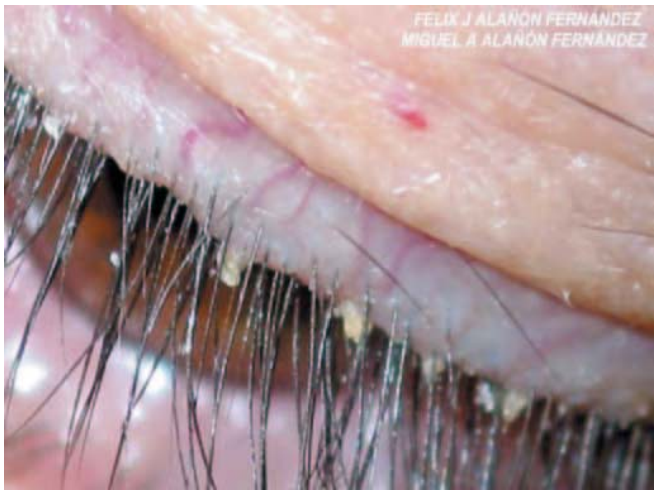

Blefaritis seborreica

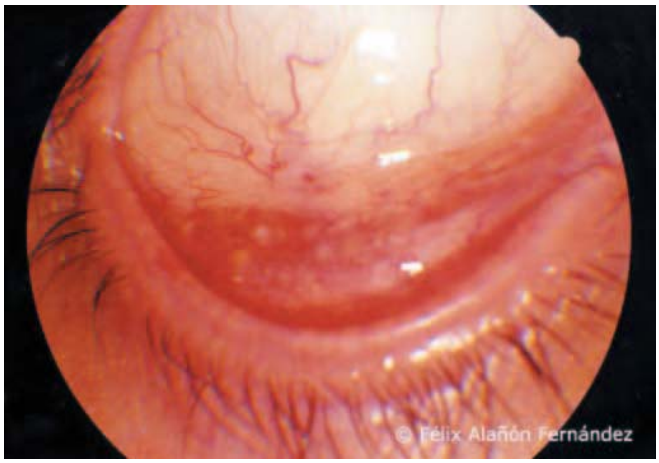

Calcificaciones subconjuntivales

Catarata morganiana

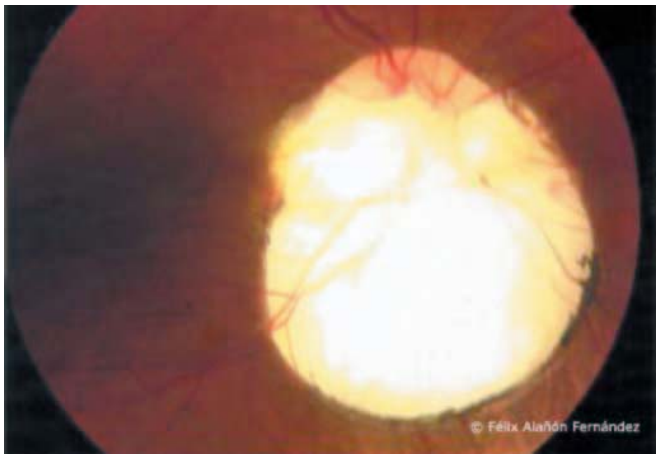

Coloboma papilar

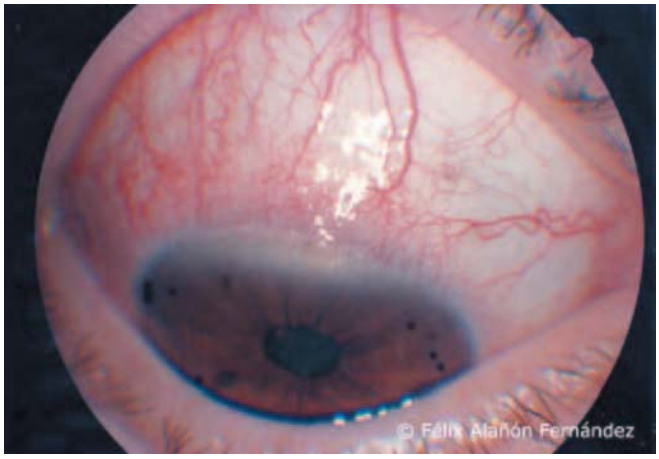

Conjuntivitis hiperaguda

Conjuntivitis límbica superior

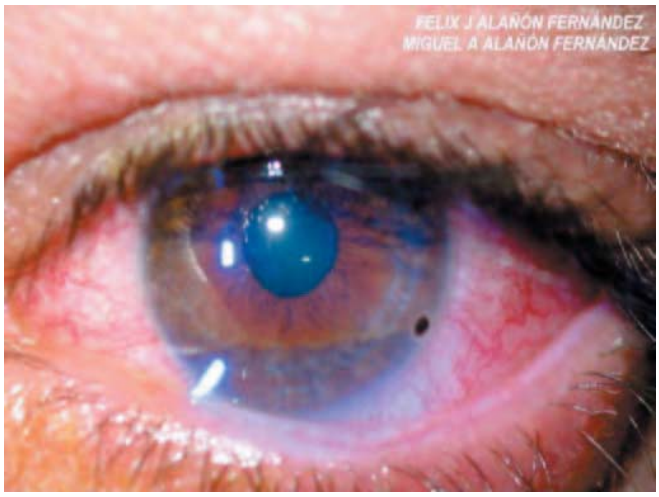

Cuerpo extraño corneal

Dacriocistitis aguda

Degeneración macular asociada a la edad

Ectropión

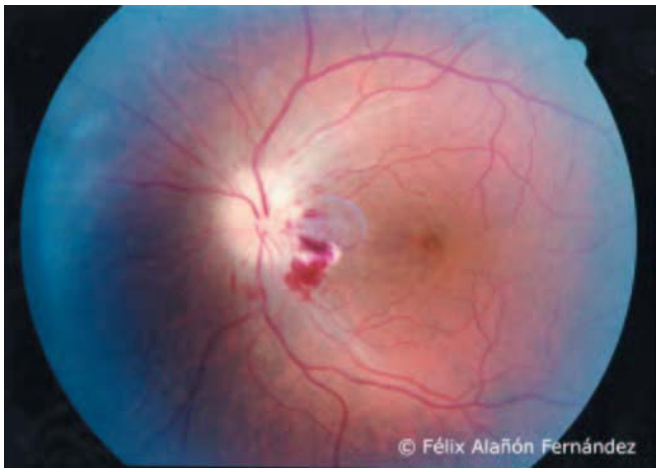

Edema de papila

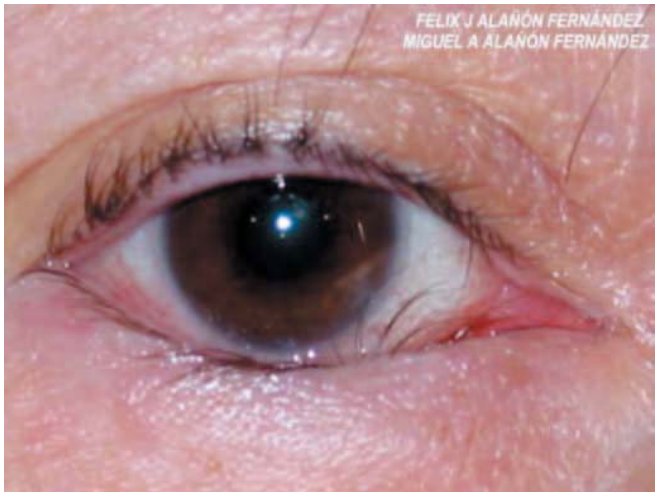

Entropión

Erosión corneal

Excavación papilar glaucomatosa

Fondo de ojo normal

Hifema

Obstrucción vena central de la retina

Orzuelo interno

Pseudotumor orbitario

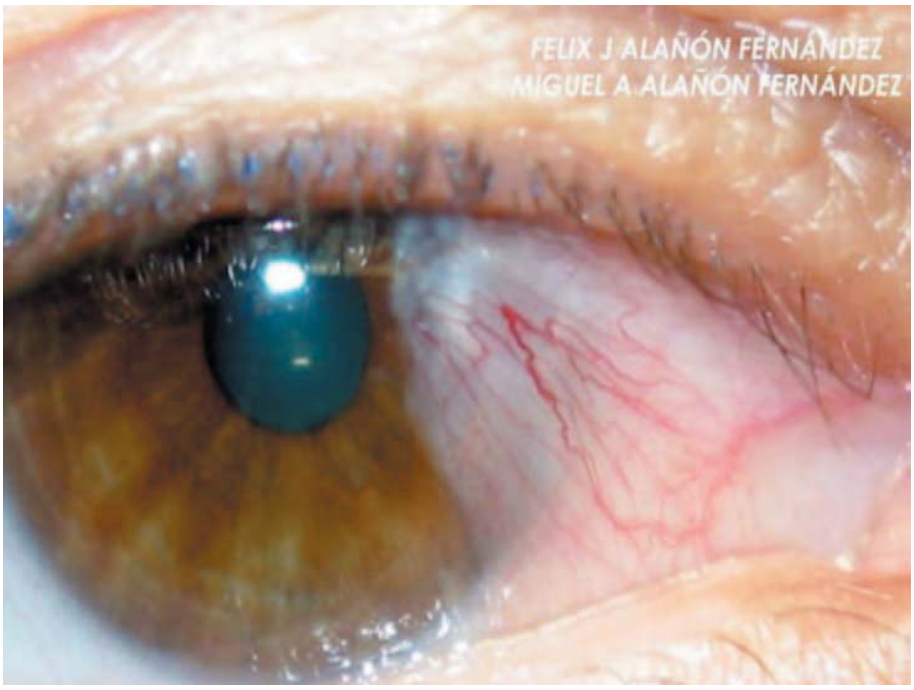

Pterigion

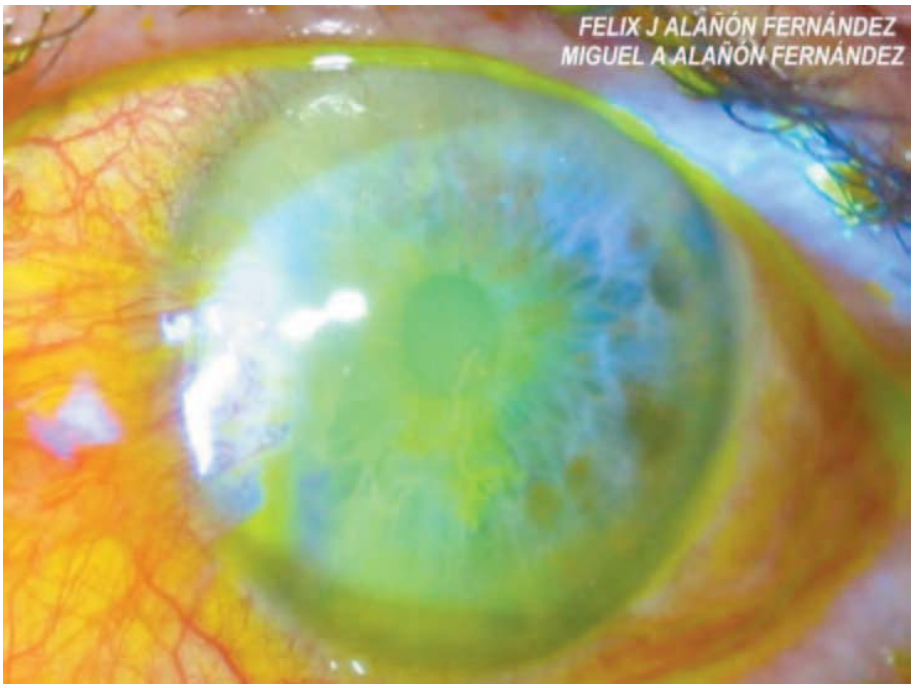

Queratitis dentrítica

Retinopatía diabética de fondo muy severo